



PATIENT

Charlie LeConti

PRESENTING CLINICAL SIGNS

History: Grade IV/VI systolic murmur; no clinical signs.

SPECIES

Canine

ECHOCARDIOGRAM FINDINGS

2D, m-mode, color flow and Doppler imaging is available.

Left ventricle: The LV diameter is minimally dilated with adequate myocardial function. LV wall thicknesses are normal.

BREED

Mix

Left atrium: The left atrium is mildly dilated.

Mitral valve: The mitral valve is diffusely thickened with minimal prolapse into the left atrial lumen. Moderate eccentric mitral regurgitation with a normal velocity.

SEX

Male Neutered

Aortic valve/aorta: The aortic valve is normal in morphology and mobility. Normal aortic outflow velocity; laminar flow. No aortic insufficiency.

Right ventricle: Normal right ventricular diameter and morphology indicating no overt evidence of pulmonary arterial hypertension.

Right atrium: Normal RA dimension.

AGE

9 years

Tricuspid valve: The tricuspid valve appears normal with no tricuspid regurgitation.

Pulmonic valve/pulmonary artery: The pulmonic valve is normal in morphology and mobility. No pulmonic insufficiency. Normal RVOT velocity; laminar flow.

Pericardium/other: No pericardial or pleural effusion noted. No obvious cardiac masses.

WEIGHT

18lbs

2-Dimensional Measurements

Ao diam (cm)	1.2
LA diam (cm)	1.8
LA:Ao (Swe)	1.5
IVS thickness (cm)	0.7
LVID diastole (cm)	2.6
PW thickness (cm)	0.7
LVID systole (cm)	1.3
FS (%)	51

Doppler Measurements

PV Vmax (m/s)	0.71
AoV Vmax (m/s)	1.4
MR Vmax (m/s)	5.0
TR Vmax (m/s)	NA
TR PG (mmHg)	NA

INTERPRETED BY

Maggie Machen
Lamy, DVM
DACVIM (Cardiology)

INTERPRETATION OF THE FINDINGS

The cause of the murmur is chronic degenerative valve disease causing moderate mitral regurgitation. Lack of significant left atrial enlargement indicates the current risk for complication is low. No concurrent issues such as systolic dysfunction or pulmonary hypertension are noted in this study. Assessment of progression in the future will help predict long term prognosis, which is highly variable at this stage (B1).

IMAGING PERFORMED BY

Pamela Harrigan,
RDCS

RECOMMENDATIONS

- In an asymptomatic dog without significant left atrial enlargement, no cardiac medications are clearly indicated.
- Omega fatty acid supplementation and mild salt restriction may be of some long-term benefit.
- Anesthetic risk is considered mild if needed. Cardiac protective drug choices (opioid/benzodiazepine premedication, propofol or alfaxalone induction, isoflurane gas) are recommended. Pre-oxygenate for 5-10 minutes prior to induction. Monitor for arrhythmias, hypotension, and hypoxia both intra and post-operatively and intervene as necessary. Mild IV fluid restriction is recommended to avoid fluid

HOSPITAL NAME

Mashpee Veterinary
Hospital

REFERRING VET

Dr. Oldham

INVOICE

22562

DATE

2/14/22



PATIENT

Charlie LeConti

overload. Avoid heart rate stimulating drugs such as atropine unless clinically indicated.

- Monitor for development of a cough, labored breathing, exercise intolerance or collapse episodes.

SPECIES

Canine

PLAN

- Recommend conservative monitoring with a recheck echocardiogram in 6 months, sooner if any development of clinical signs.

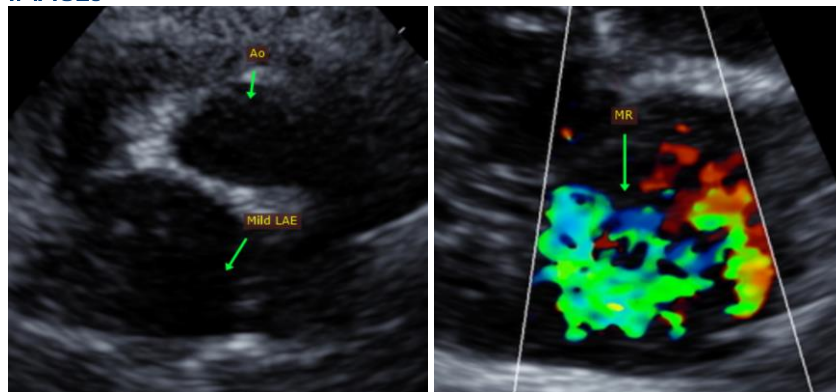
BREED

Mix

IMAGES

SEX

Male Neutered



AGE

9 years

WEIGHT

18lbs

INTERPRETED BY

Maggie Machen Lamy, DVM
DACVIM (Cardiology)

The information and recommendations provided are based on the images presented by the referring veterinarian. No evaluation can be communicated regarding pathology that was not visible in the image/video clips provided.

Thank you for this referral. This report was generated using transcription software, and minor dictation errors may be present. If the clinical or image interpretation does not parallel your findings or if I can be of any further assistance, please contact me.

IMAGING PERFORMED BY

Pamela Harrigan, RDCS

Maggie Machen Lamy, DVM
Diplomate of the American College of Veterinary Internal Medicine (Cardiology)
info@sonopath.com

HOSPITAL NAME

Mashpee Veterinary Hospital

REFERRING VET

Dr. Oldham

INVOICE

22562

DATE

2/14/22